

Reverse Wenckebach “pseudo-supernormal” conduction or paroxysmal atrioventricular block

Zahid M.^{1,2}, Arora S.²

¹Excelsa Health System, Westmoreland Regional Hospital, Greensburg,

²Department of Developmental Biology, University of Pittsburgh, PA, USA

Address for correspondence: Dr. Maliha Zahid, Excelsa Health Cardiology, 8775 Norwin Avenue, Suite 4, Irwin, PA15644, USA. E-mail: maz7@pitt.edu

ABSTRACT

Paroxysmal atrioventricular-block is a poorly-recognized cause of atrioventricular conduction abnormality leading to syncope and can be fatal. Here we report a case of paroxysmal atrioventricular-block presenting as syncope treated effectively with pacemaker implantation and review the current literature on prevalence, known mechanisms and treatment for it. Importantly we provide the diagnostically important differentiating points between vagally mediated block and paroxysmal atrioventricular-block as well as the highlight the vastly varying prognosis between the two.

Key words: Paroxysmal AV-block, reverse wenckebach, syncope

INTRODUCTION

Here we present a case of paroxysmal atrioventricular block presenting as syncope and elaborate on the electrophysiological events leading to the particular electrocardiographic findings associated with it.

CASE REPORT

An 83-year-old Caucasian female with borderline hypertension and no prior cardiac history presented with intermittent headaches, dizziness, and an episode of syncope. An electrocardiogram (ECG) was obtained which showed normal sinus rhythm with normal PR interval and QRS duration [Figure 1]. She was admitted to a monitored bed and next day, developed intermittent atrioventricular block in a Wenckebach fashion [Figure 2] followed by sudden onset complete heart block. An echocardiogram revealed preserved

ventricular function and no significant valvular pathology. Patient underwent placement of a dual-chamber pacemaker uneventfully. Over a follow-up period of 6 months, patient remained symptom free.

COMMENT

Wenckebach's periodicity is characterized by a pattern of group beating where the PR interval gradually prolongs resulting in a non-conducted beat. The PR interval for the first conducted beat is smaller than the PR interval of the last conducted beat. Our patient demonstrated an apparent reverse 3:2 Wenckebach phenomenon [Figure 2]. The first conducted P wave after the block had longer PR interval compared to subsequent conducted beat. Moreover, the first conducted beat after the pause had a wider ventricular complex, compared to the subsequent complex. This is a paradoxical response since one would expect the His-Purkinje system to recover from its refractory state after the pause, resulting in a narrow rather than wide complex.

This abnormal conduction (longer PR interval and wider QRS duration) in the first conducted P wave after the pause [beat 1; Figure 2] or an apparent “supernormal” conduction in the subsequent beat [beat

Access this article online	
Quick Response Code:	Website: www.jcdronline.com
	DOI: 10.4103/0975-3583.98898

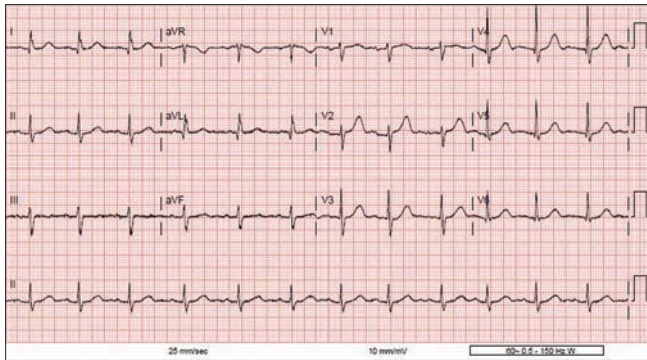


Figure 1: Twelve-lead EKG on admission demonstrating normal sinus rhythm and normal atrioventricular conduction

2; Figure 2] is the result of a diseased His-Purkinje system with bradycardia induced phase-4 depolarization of His-Purkinje system. Our patient has underlying 3:2 atrio-ventricular block resulting in every third beat to be blocked in the proximal His-Purkinje system. This delay results in spontaneous initiation of phase-4 depolarization in the distal His-Purkinje system, specifically the left anterior fascicle and right bundle. Phase-4 depolarization is a property of the heart's conduction system, and is responsible for its automaticity. It occurs after complete repolarization, when the membrane potential starts to depolarize, and upon reaching a critical threshold, a new action potential is generated by inward calcium current. Phase-4 depolarization can also be seen in diseased His-Purkinje system, and since this system lacks inward calcium channels, a new action potential cannot be generated. On the contrary, once the membrane potential starts to move towards zero, voltage gated sodium channels are inactivated and no longer able to conduct electrical impulses, resulting in complete block.

In our patient, a pause due to a blocked beat in the proximal portion of His-bundle resulted in development of phase-4 depolarization in left anterior fascicle and right bundle which blocked the subsequent conduction due to lack of availability of active Na^+ channels. The posterior fascicle conducted, but slower than usual, resulting in prolonged PR interval and a wide QRS complex with morphology of a bi-fascicular block [beat 1; Figure 2]. The next beat conducted through the AV node and the proximal portion of His-bundle and since there is no delay, phase-4 depolarization did not develop resulting in normal QRS complex. The subsequent beat [beat 3; Figure 2] was blocked in the proximal diseased His-Purkinje system due to fatigue phenomenon, which provides the necessary delay for phase-4 depolarization

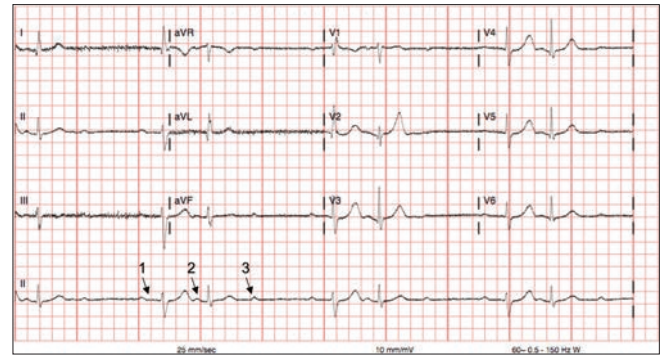


Figure 2: Twelve-lead EKG of patient showing paroxysmal AV-Block and phase-4 depolarization of the distal His-Purkinje system occurring after a blocked beat (first arrow) leading to conduction with a RBBB and LAFB in the first conducted beat after the pause

to develop in the left anterior and right bundle, hence repeating the cycle. If the phase-4 depolarization had reached a critical threshold, there would be a conduction block in the posterior fascicle as well resulting in complete heart block, called paroxysmal AV block (AVB), which was indeed seen in our patient.

Paroxysmal AV-block was first described by Sachs and Traynor in 1933,^[1] followed by a report of two cases of paroxysmal AVB precipitated by a premature atrial complex by Coumel *et al.* in 1971.^[2] Sudden change from normal 1:1 AV-conduction to complete heart block is precipitated by a pause following a premature atrial, ventricular or His-extrasystole triggering phase-4 depolarization in a diseased His-Purkinje system. Subsequent impulses continue to find the diseased conduction system during its phase-4 leading to inability to depolarize. This AV block persists until another PAC or PVC captures the His-Purkinje system prior to phase-4 depolarization, thereby restoring normal conduction. Prompt recognition of paroxysmal AVB is essential because of its potential to lead to sudden cardiac death, which can be prevented by permanent pacemaker implantation.

Little is known about the prevalence of paroxysmal AVB. In one study of 52 patients with complete/incomplete RBBB, syncope and negative EPS, implantable loop recorders showed development of complete heart block in 13 (25%), but only 5 (10%) had complete heart block triggered by a premature beat.^[3] In patients with paroxysmal AVB, the baseline EKG may be normal (as was in our patient) but more commonly shows evidence of distal conduction disease. From a review of the published series,^[4-6] evidence of RBBB with or without left anterior fascicular block is

the commonest presentation. It is equally common in men and women, with prevalence reported to increase with age.

One of the important entities to differentiate paroxysmal AVB from is vagally mediated AVB. This is clinically important as the latter has a benign prognosis and no studies have shown benefit of prophylactic pacemaker implantation in vagally mediated AVB.^[7] Paroxysmal AVB is initiated by a premature beat followed by a pause and in some cases by tachycardia leading to suppression of AV-conduction. In vagally mediated AVB, there is gradual slowing with P-P and P-R prolongation prior to AVB or sinus arrest. In paroxysmal AVB there is sudden development of AVB and symptoms whereas with vagally mediated AVB, the clinical history will be highly suggestive of heightened vagal tone.

TAKE-HOME POINTS

- Paroxysmal AV-block is a little-known, but important, cause of development of sudden onset complete heart block that can lead to ventricular asystole or sudden cardiac death, which can be prevented with implantation of a pacemaker.
- A normal ECG at baseline does not rule out presence of paroxysmal AVB although underlying His-Purkinje conduction abnormalities are frequently

present.

- Pause dependent Phase-4 depolarization in the diseased His-Purkinje system is thought to be the underlying pathophysiological mechanism.

REFERENCES

1. Sachs A, Traynor RL. Paroxysmal complete auriculo-ventricular heart-block. A case report. *Am Heart J* 1933;9:267-71.
2. Coumel P, Fabiato A, Waynberger M, Motte G, Slama R, Bouvrain Y. Bradycardia-dependent atrio-ventricular block. Report of two cases of A-V block elicited by premature beats. *J Electrocardiol* 1971;4:168-77.
3. Brignole M, Menozzi C, Moya A, Garcia-Civera R, Mont L, *et al.* Mechanism of syncope in patients with bundle branch block and negative electrophysiological test. *Circulation* 2001;104:2045-50.
4. Rosenbaum MB, Elizari MV, Levi RJ, Nau GJ. Paroxysmal atrioventricular block related to hypopolarization and spontaneous diastolic depolarization. *Chest* 1973;63:678-88.
5. Shohat-Zabarski R, Iakobishvili Z, Kusniec J, Mazur A, Strasberg B. Paroxysmal atrioventricular block: clinical experience with 20 patients. *Int J Cardiol* 2004;97:399-405.
6. Lee S, Wellens HJ, Josephson ME. Paroxysmal atrioventricular block. *Heart Rhythm* 2009;6:1229-34.
7. Connolly SJ, Sheldon R, Thorpe KE, Roberts RS, Ellenbogen KA, *et al.* Pacemaker therapy for prevention of syncope in patients with recurrent severe vasovagal syncope: Second Vasovagal Pacemaker Study (VPS II): A randomized trial. *JAMA* 2003;289:2224-9.

How to cite this article: Zahid M, Arora S. Reverse Wenckebach "pseudo-supernormal" conduction or paroxysmal atrioventricular block. *J Cardiovasc Dis Res* 2012;3:225-7.

Source of Support: Nil, **Conflict of Interest:** None declared.

Announcement

Android App



A free application to browse and search the journal's content is now available for Android based mobiles and devices. The application provides "Table of Contents" of the latest issues, which are stored on the device for future offline browsing. Internet connection is required to access the back issues and search facility. The application is compatible with all the versions of Android. The application can be downloaded from <https://market.android.com/details?id=comm.app.medknow>. For suggestions and comments do write back to us.